

# A Novel High-Quality Equine Standing CT Scanner: The Asto CT Equina®

David Ergun<sup>1,3</sup>, PhD, CEO

Sabrina Brounts<sup>1,2</sup>, DVM, MS, PhD, DACVS/ECVS, DACVSMR, Scientific Advisor

Rock Mackie<sup>1,3</sup>, PhD, Chief Innovation Officer

<sup>1</sup>Asto CT Inc, Middleton, WI USA

<sup>2</sup>School of Veterinary Medicine, University of Wisconsin-Madison, Madison, WI USA

<sup>3</sup>Medical Physics, University of Wisconsin-Madison, Madison, WI USA

## INTRODUCTION

With hundreds of thousands of horses being used for race, show, and recreation throughout the world, appropriate management of injuries and illness over the lifetime of the horse is a high priority in equine veterinary care. While there are many facets of equine medical management, imaging often plays a very small role despite its tremendous potential to improve the life of the equine patient. Low cost and widely available technologies like planar radiography and ultrasound often lack diagnostic sensitivity while advanced volumetric imaging technologies like computed tomography (CT) have required anesthesia and complex

positioning making them impractical for most practices. Some advanced imaging systems also rely on scanning systems not designed for the equine patient leading to poor reliability and image quality. A new tool, Equina® (Asto CT, Middleton, WI), has been developed and specifically designed for a veterinarian to safely image a sedated standing horse in a natural load-bearing position solving some of the key barriers to equine CT imaging. In this paper, we provide a brief description of the key features of the Equina® system and describe how it can move us into a new equine standard-of-care.

## HOW DOES EQUINA® WORK?

The Equina® is a dual direction CT scanner that can be used to image a sedated, standing horse. The critical innovation is the incorporation of flexible positioning with a clinical grade CT gantry. The flexibility of movement allows the CT gantry to be moved into the appropriate position for imaging the limbs or the head and neck without requiring complex positioning of the horse or use of general anesthesia. For image acquisition, the scanner slides while the patient remains fixed.

Image acquisition and reconstruction use a state-of-the-art helical fan beam CT scanner powered with a 240V single-phase 30A uninterruptible power supply (UPS). Scanning is performed

with a low-dose exposure at 160 kVp at 1 sec per revolution; there are 24 detector rows with a helical pitch of 0.55. The slice acquisition rate is 36 slices/sec with an image acquisition matrix of 1024 x 1024 and resolution at the isocenter of 0.75 mm. The CT gantry bore diameter is 75 cm with a field of view (FOV) of 75 cm – everything within the opening of the bore is imaged. This is a very important design feature as it greatly facilitates patient positioning for both limb and head scans of the standing horse. Because of this feature, no scout scan is required. The maximum scan distance for scanning limbs is 75 cm at 2 cm/sec and for head and neck is 92 cm at 2 cm/sec.



Figure 1. Set-up for a CT scan of distal thoracic limbs in a horse. The CT gantry sits below the system platform (A). The limb pairs are positioned with the bore of the CT gantry for scanning (B) (photo's courtesy of Dr. C Whitton).

The operation and movement of the CT scanner is controlled by a simple hand-held controller with pushbutton controls. This allows the operator to be nearby the patient and the patient handlers while scanning take place. If needed for patient safety, a “release” switch on the System Pendant Controller can be activated to quickly move the CT gantry back to its home position under the floor or during a scan of the proximal limbs.


The inherently low power of the CT scanner, along with a high level of internal self-shielding allow patient handlers with protective radiation shielding (standard shielding apron, thyroid, and eye shield only) to stay in the room while scanning takes place to optimize handling and ensure the maximum safety of the patient.

For limb scanning, the CT system scans either the two thoracic (front) limbs, or the two pelvic (rear) limbs in a natural load-bearing position. Referring to Figure 1, the sedated horse is walked across the CT gantry and the limb pairs are positioned within the bore of a CT gantry, which sits below the system platform.

The bore of the CT gantry is 75 cm in diameter, which easily accommodates a wide variety of sizes. Because the system can image the entire area within the bore, the operator need only ensure that the horse comfortably straddles the gantry. The operator then mechanically raises the CT gantry to the appropriate level (start position) to scan the location of interest from proximal to distal. The compact profile allows imaging up to mid-radius or mid-tarsus. Once the CT gantry is in the start position, the operator initiates the scan. Scanstake less than 20 seconds and ends when the gantry is back below the system platform. After scanning, the horse can be taken from the platform.

For head and neck scanning, the CT gantry can be easily raised and rotated for horizontal scanning of the head and neck of the horse. Referring to Figure 2, the horse is led into stocks with a cushioned headrest. The gantry can be raised or lowered to a height that is comfortable for the horse. With the head comfortably resting on the head rest, the CT gantry is advanced caudally, and scanning is performed in a rostral direction. Depending on the area to be imaged, scans can take up to 45 seconds.

## EQUINA® IN CLINICAL PRACTICE - LIMBS



*Figure 2. Set-up for a CT scan of the head and neck region in a horse. The CT gantry is raised from the floor and rotated into a vertical position for horizontal scanning (A). The sedated horse stands in the stocks with its head on a headrest (B).*

Lameness is a very common problem in horses and can be challenging to diagnose. Diagnostic imaging plays a large part in finding the cause of the lameness. Radiography and ultrasound have played historically a major role in the everyday lameness work-up; however early detection of physiologic changes associated with injury can be challenging at times. The introduction of standing CT technology makes it possible to have this modality play an essential part in the lameness examination. Standing CT images have the potential to provide clear and detailed bone and soft tissue imaging of the lower limbs. These images improve the equine veterinarian's ability to accurately define and identify abnormalities in the limbs, which may lead to better management/rehabilitation of the injury or even prevent future injury.

Equina® has already been used to assess the limbs of several thousand equine patients. In a study of 167 horses from the University of Wisconsin and University of Melbourne<sup>1</sup>, 88 horses had diagnosable findings in their scans. The most common findings for foot/pastern was navicular syndrome and for fetlock scans was palmar/plantar osteochondral disease (POD). When a comparison was made between cases that had both radiographs and a CT scan performed, only in 25% of these cases (22/88) was the diagnosis made with radiographs, indicating up to a 75% false negative rate for radiographs alone. Importantly, no complications or adverse events were experienced by any of the horses in the study and no equipment failures occurred. These early data show that the Equina® is safe and effective for diagnosing conditions of the lower limbs that would largely be missed by radiography.

## EQUINA® IN CLINICAL PRACTICE - HEAD

The versatility of the Equina® scanner makes it possible to also scan the head and neck of horses quickly. Radiographs of the head can be difficult to interpret due to the complexity and superimposition of the anatomical structures of the head. Many older horses are diagnosed with tooth and sinus problems. The Equina® can be very useful and safe to use in routine imaging of the head.

A recent study of the use of the Equina® on 120 horses that underwent head and neck scanning showed a higher level of

diagnostic efficacy with CT imaging with the Equina® than conventional radiography<sup>2</sup>. Dental disease and sinus space occupying lesions (SOL) were the most common diagnosis in the head CT scans that were conducted. CT imaging of the neck showed that nuchal bursitis and spinal injuries were most of the cases presented in this study. Additional work is still needed to assess the full potential of the Equina® for scanning of the full neck region. No adverse events were associated with scanning the heads and necks of these horses, which is very similar to the use of the Equina® for scanning of the limbs.

## THE UNIQUE FEATURES OF THE EQUINA®

The Equina® was purpose-built in consultation with equine veterinarians to rapidly acquire CT images from equine patients of all conformations and sizes. The strength of the system includes considerations for the weight and power of the horse even in the extreme conditions of kicking or rearing up. Horse-oriented design throughout the system has informed the choice of colors, materials, sounds, environmental conditions, and cleanability:

- The leading surface of the CT scanner has a laser curtain to prevent the scanner from hitting the patient, either when lifting for limb scans, or translating for head and neck scans.
- The top of the CT gantry is covered with a rugged, non-slip, shock-absorbing surface that a horse can safely walk across. The system can also be used to perform image-guided surgery on a limb while the patient is standing in the Equina® unit on the bore pedestal. In this manner, CT imaging can be used for intraoperative imaging as needed to assist during a surgical procedure.
- The CT gantry and motion system is sealed to protect the equipment against ingress of dust, and against water or urine. Surfaces are easily cleaned and maintained.

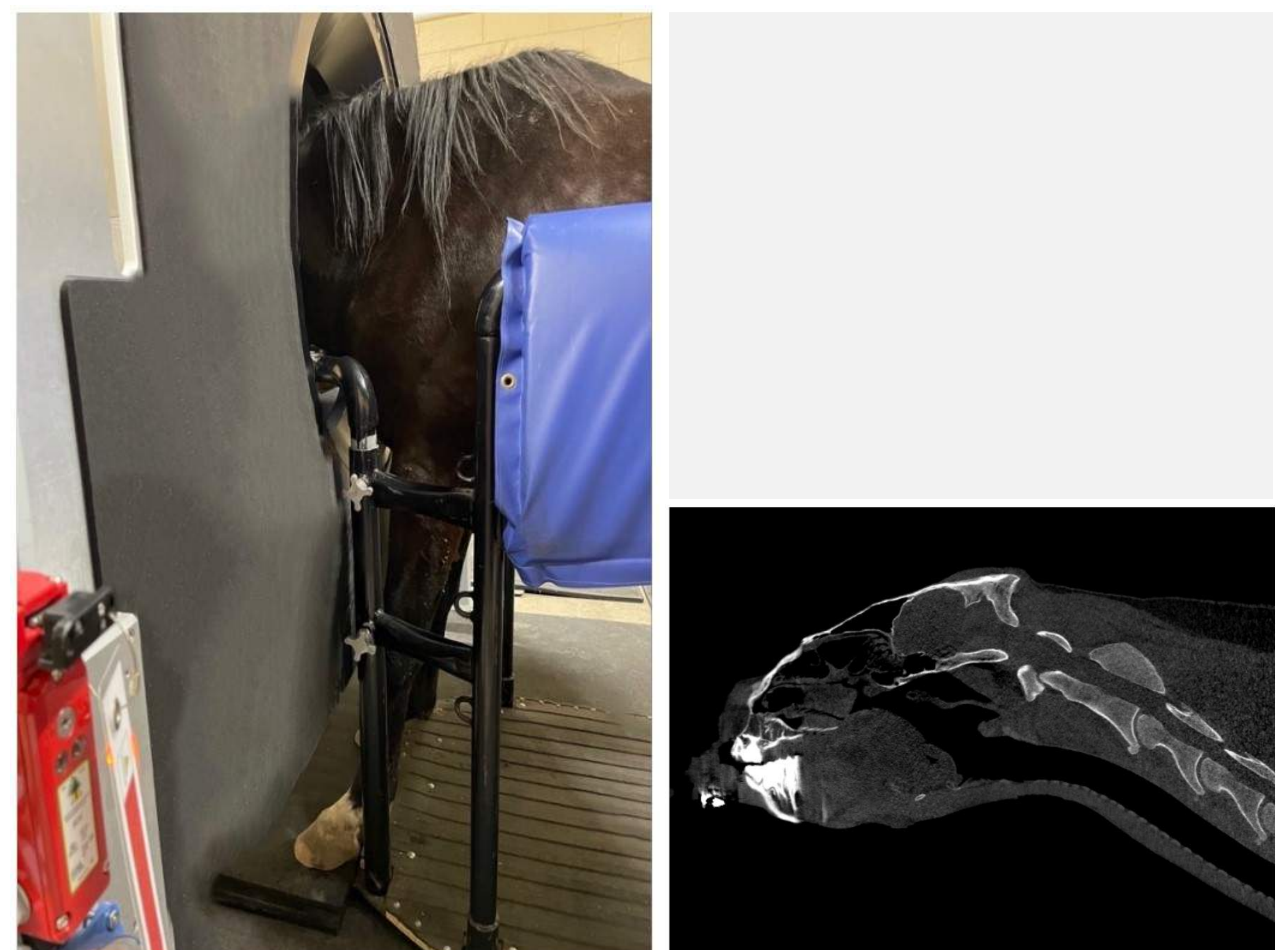


Figure 3. Standing head and neck scan for an equine patient showing cervical reach to C4-C5.

The opening at the front surface of the CT gantry is 92 cm and tapers internally to 75 cm. This allows the patient to be placed into the bore opening for cervical spine and proximal limb coverage. Because of the wide opening, positioning permits routine imaging standing to C5 in the neck region (Figure 3).

The scanning techniques, along with the imaging features of the system are specifically tailored for imaging equine anatomy. The scanning technique uses 160kVp which is ideal for imaging subchondral bone. Special bone- and soft-tissue reconstruction algorithms are available for imaging both bone and soft tissue. A full reconstruction field encompassing the entire 75 cm bore

diameter is available immediately after the scan for review. Filtered retro reconstructions include:

- Bone slice set (Figure 4) – processed with a filter kernel to enhance bone features.
- Soft tissue slice set (Figure 5) – processed with a filter kernel to enhance soft tissue features.

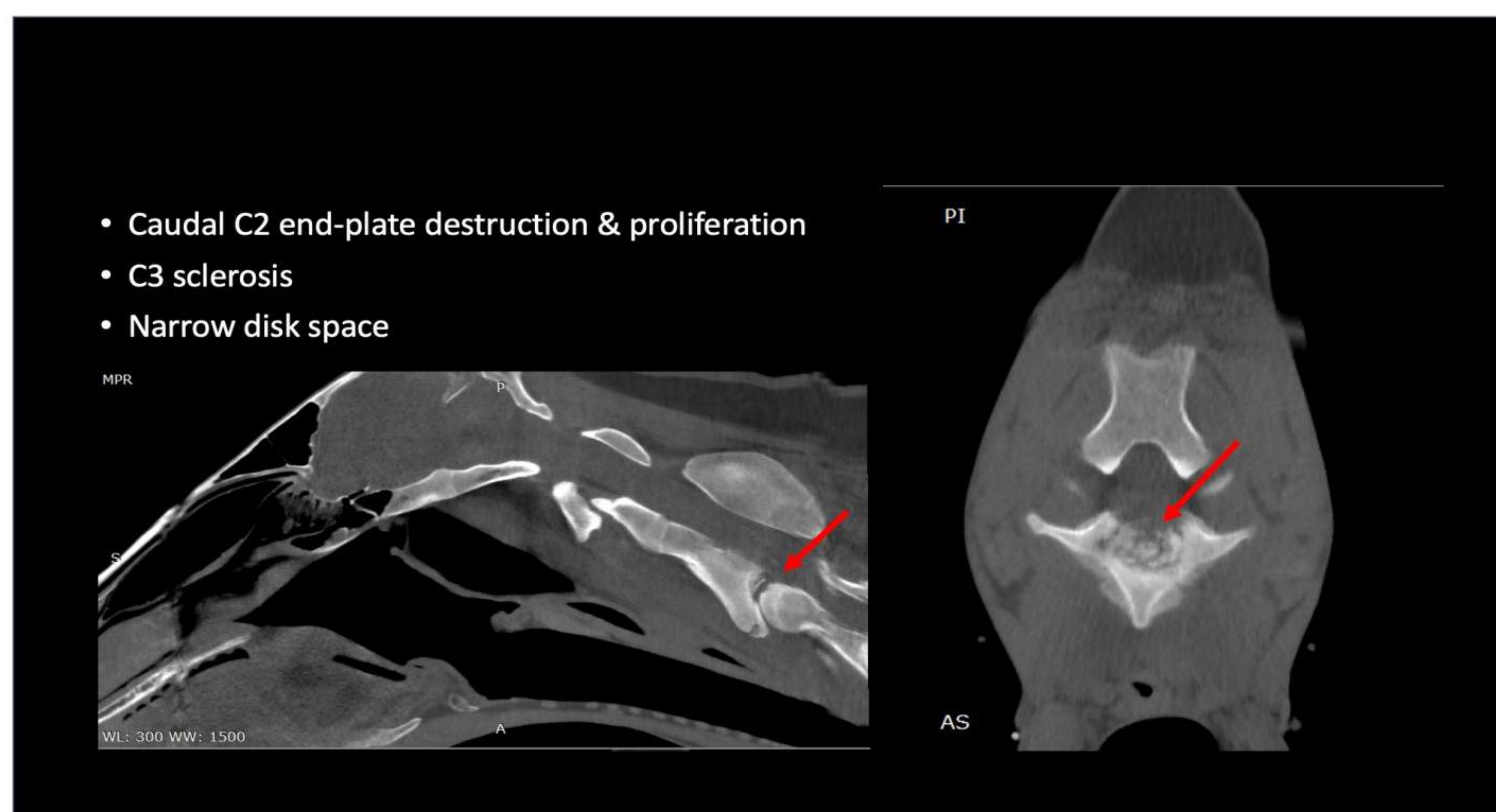


Figure 4. CT data set processed with Bone Filter for 2yr-old Morgan with neurologic disorder.

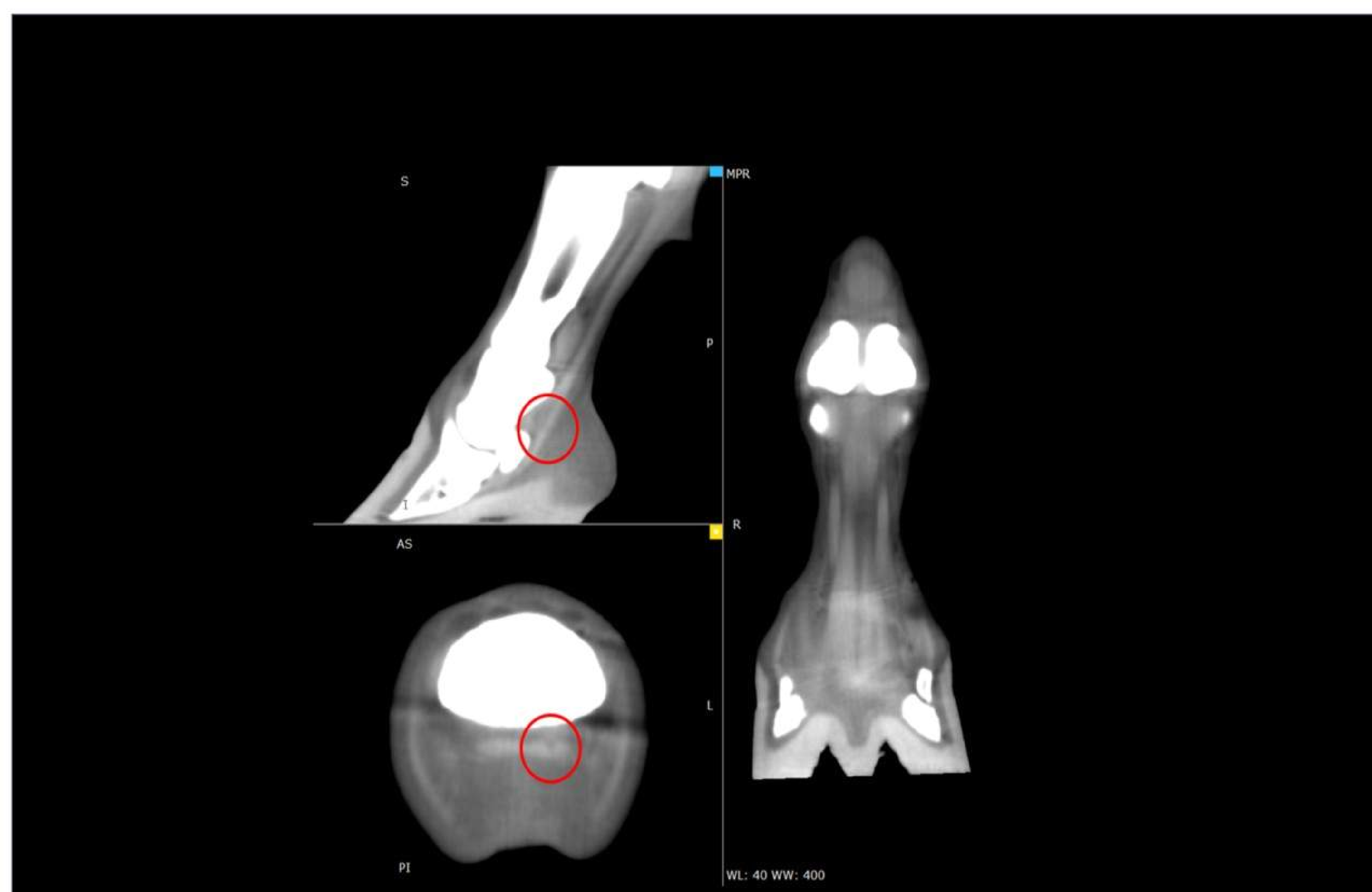

Figure 5. CT data set processed with Soft Tissue filter for 13yr-old Quarter Horse with tendon lesion.

## TRANSFORMING THE STANDARD OF CARE

---

The Equina® is being used in multiple practices today and has shown the added value that standing CT imaging can bring to an equine practice. By providing fast, safe, and standing CT scanning with the Equina®, equine patients and their owners can expect a higher standard of care for their horses.

The Equina® can be used as a diagnostic tool in several areas of routine equine practice. These include for example:

- Pre-purchase examinations in horses.
- Lameness examinations and management in horses.
- Pre-race or during training monitoring for stress fractures in racehorses and other sport horses.
- Injury monitoring during rehabilitation of sport horses to individualize their rehabilitation program.
- Dental care of horses.
- Image-guided surgery for limbs.
- Surgical planning for limbs, heads and necks.

## SUMMARY

---

Computed Tomography has changed equine practice over the recent decades. CT imaging has been the gold standard for imaging of the head as well as orthopedic problems. However, the use of CT imaging has been limited in certain circumstances due to the need of general anesthesia, which can add extra expense, personnel, and time – not to mention the extra morbidity and mortality that general anesthesia can bring.

The Equina® is an easy to use standing helical fan beam CT system that has the versatility to be used in both head and neck as well as limb imaging. It allows for fast, safe, and standing CT imaging with minimal stress to the horse or change to its training schedule. This CT system is opening the door to a higher level of imaging as well as a standard of care to all horse owners and trainers.

## REFERENCES

---

1. Brounts SH, Lund JR, Whitton RC, Ergun DL, Muir P. Use of a novel helical fan beam imaging system for computed tomography of the distal limb in sedated standing horses: 167 cases (2019–2020). *J Am Vet Med.* 2022;260(11):1351-1360. doi.org/10.2460/javma.21.10.0439
2. Brounts SH, Henry T, Lund JR, Whitton RC, Ergun DL, Muir P. Use of a novel helical fan beam imaging system for computed tomography of the head and neck in sedated standing horses: 120 cases (2019–2020). *J Am Vet Med.* 2022;260(11):1361-1368. doi.org/10.2460/javma.21.10.0471

©2022 Asto CT Inc – All rights reserved. Asto CT and Equina are registered trademarks of Asto CT.

Dr. Ergun, Dr. Brounts and Dr. Mackie have financial interest in Asto CT